

# Clinical Implant Dentistry and Related Research

2005 ♪ Volume 7 ♪ Number 1

ISSN 1523-0899

**DECKER**  
pîr'ē·ōd'i·kəls X

Now indexed in  
Index Medicus and MEDLINE

# A Prospective Study of Immediate Functional Loading, Following the Teeth in a Day™ Protocol: A Case Series of 55 Consecutive Edentulous Maxillas

Stephen F. Balshi, BBE;\* Glenn J. Wolfinger, DMD, FACP;†‡ Thomas J. Balshi, DDS, FACP†

---

## ABSTRACT

*Background:* Immediate loading of dental implants is increasingly gaining recognition as a viable option for both patient and clinician.

*Purpose:* The aim of this study was to evaluate the results of 55 patients in a clinical investigation of immediate functional loading of Brånemark System® implants (Nobel Biocare USA, Yorba Linda, CA) in edentulous maxillas. Its further purpose is to suggest a reliable and evidence-based protocol for immediate implant loading of full-arch prostheses in the maxilla.

*Materials and Methods:* A total of 552 Brånemark System implants were placed in immediate extraction or healed sites; a mean number of 10 implants were placed per patient. The healthy subjects in need of full-arch maxillary implant reconstruction were treated between December 1999 and February 2004; 522 of the 552 implants were immediately loaded with screw-retained all-acrylic fixed prostheses at the time of surgery. Approximately 4 to 6 months later, the 30 submerged implants were uncovered, and a definitive metal-reinforced prosthesis was delivered to each patient.

*Results:* The immediately loaded implant cumulative survival rate was 99.0% for these patients. The prosthesis survival rate was 100%.

*Conclusions:* The results of this prospective study of full-arch maxillary immediate loading suggests that this protocol is suitable for most patients in need of full maxillary implant reconstruction. The protocol, as shown in this study, is highly successful in providing a lasting state of osseointegration as the foundation for long-term stability of screw-retained fixed prostheses.

**KEY WORDS:** dental implant, full-arch reconstruction, immediate loading, maxilla, Teeth in a Day™ protocol, splinting

---

The conventional two-stage implant protocol with delayed loading has achieved excellent long-term results.<sup>1</sup> More recently many researchers have demonstrated comparable results for integration with implants using a more condensed one-stage immediate

loading protocol.<sup>2-13</sup> In many clinical situations the use of an immediate loading protocol rather than the traditional two-stage protocol benefits the patient by reducing anxiety as well as functional and aesthetic inconvenience. With the two-stage or delayed loading protocol, the patient had to abide treatment that in some instances reached 2 years in duration. The patient also had to be willing to function for extended periods with either no teeth or with a removable prosthesis during the postsurgical healing period. Moreover since frequent follow-up visits over the course of the treatment period were required, most patients had to rely on whatever level of dental expertise was available close to their home. The use of an immediate loading protocol decreases the duration of treatment and the

---

\*Drexel University, School of Biomedical Engineering, Science and Health Systems, Philadelphia, PA, USA; director of biomedical engineering, Prosthodontics Intermedica, Fort Washington, PA, USA; †Prosthodontics Intermedica, Institute for Facial Esthetics, Fort Washington, PA, USA; ‡staff prosthodontist, VA Medical Center, Philadelphia, PA, USA

Reprint requests: Stephen F. Balshi, Prosthodontics Intermedica, 467 Pennsylvania Ave, Suite 201, Fort Washington, PA 19034, USA; e-mail: balshi2@aol.com

number of visits necessary to complete it, eliminates the discomfort that comes from wearing a removable prosthesis over the surgical site, and yields the patient the opportunity to be under the care of a prosthodontic team even at remote distances.<sup>14</sup>

Most published data on immediate loading are for implants placed in the mandible.<sup>2-13</sup> The density and mechanical properties of the bone are among the reasons why so little documentation for immediate loading in the maxillary arch has been reported. However, the limited reported studies do show the use of immediate loading protocols in the maxilla for single-tooth,<sup>15,16</sup> partially edentulous,<sup>16,17</sup> and fully edentulous applications.<sup>4,18-22</sup> When the appropriate biologic and surgical conditions present themselves, an immediate loading protocol can be highly advantageous in all areas of the jaw.

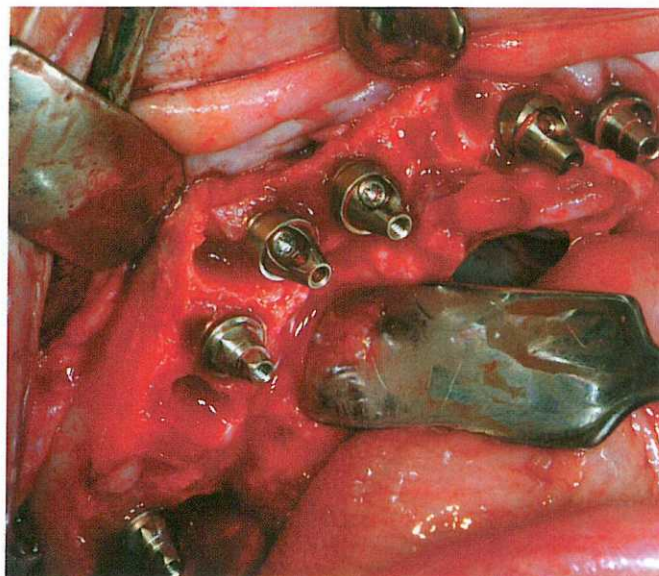
## MATERIALS AND METHODS

### Patients

Fifty-five healthy patients (31 females, 24 males) with a mean age of 57.3 years (range, 25-86 years) and who were in need of full-arch maxillary implant reconstruction were treated between December 1999 and February 2004. Inclusion criteria were based on the patients' current stable medical condition and their ability to undergo dental implant surgery. Exclusion was limited to patients with metabolic bone disease or an unstable systemic condition, such as uncontrolled diabetes, untreated hypothyroidism, or a malignancy in midtreatment. All patients were treated in a private practice setting.

### Surgical Procedure

All teeth that had advanced periodontal disease, untreatable periapical pathosis, advanced mobility, or biomechanical instability rendering them unusable in prosthetic reconstruction were extracted. All 55 Brånemark System® implants (Nobel Biocare USA, Yorba Linda, CA, USA) used in this study were surgically placed in healed bone or fresh extraction sites by a staff prosthodontist. An average of 10 implants (range, 7 to 14 implants) were placed in each maxilla. For 522 of these implants, abutments were connected immediately following implant insertion prior to flap closure (Figure 1), and a Teeth In A Day™ prosthesis (Figure 2) was made as previously described in the literature,<sup>14,23</sup>



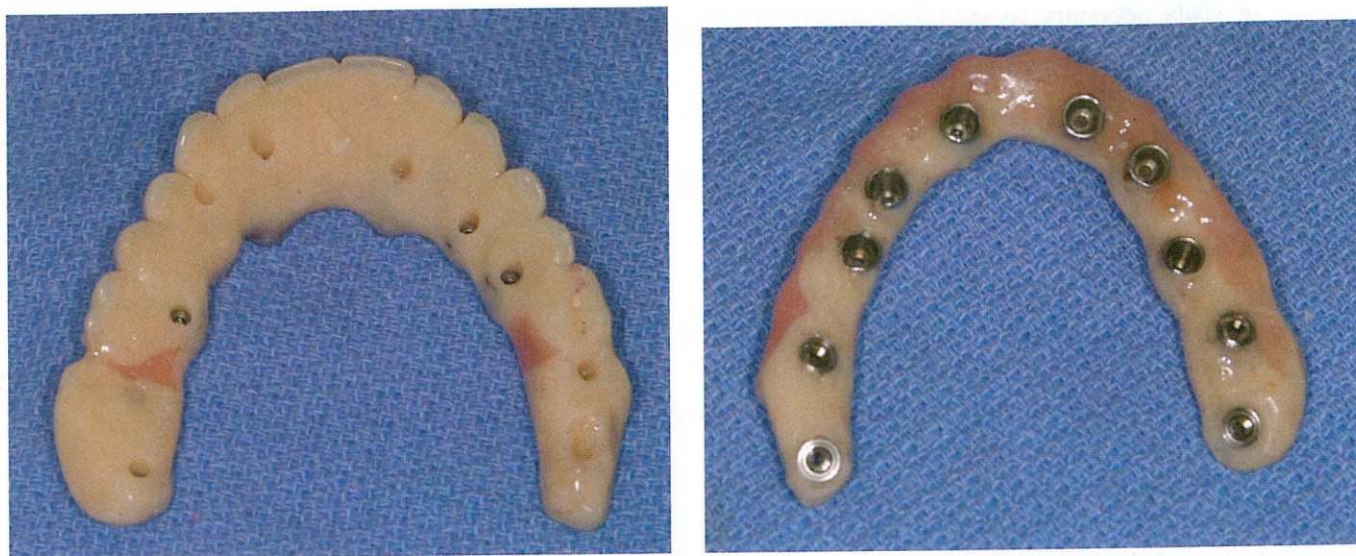**Figure 1** Maxillary Brånemark System implants with a combination of EsthetiCone™ (Nobel Biocare AB) and angulated abutments installed immediately after implant placement.

thereby immediately loading each implant. The remaining 30 implants were submerged for a healing period of approximately 4 to 6 months at the clinician's discretion, largely because of poor primary stability and/or inferior bone quality at the implant site.

The majority (486) of the implants used in this study had oxidized titanium surfaces (TiUnite™, Nobel Biocare USA); the 4 × 15 mm Brånemark System Mk IV TiUnite regular-platform implant was the most frequently used implant. Nineteen regular threaded machined-surfaced Brånemark implants and 19 Mk IV Ebon (Nobel Biocare AB, Göteborg, Sweden) machined-surfaced implants were implanted; however, these implant types were mainly used prior to the inception of the TiUnite implant. Twenty-eight machined-surfaced zygomatic implants were placed (Table 1). All 55 patients received a prosthesis that spanned from second molar to second molar. One-hundred two implants were placed in the pterygo-maxillary region (Figure 3), meaning that 51 of the 55 patients had implants placed distal to the prosthesis, eliminating any cantilevers.<sup>24</sup>

### Prosthetic Procedure

After abutment connection of the immediately loaded implants, a screw-retained all-acrylic fixed prosthesis was placed. All patients were instructed to maintain a soft diet for the first 12 weeks or until the final porcelain-fused-to-gold prosthesis was delivered (Figure 4). The



**Figure 2** An all-acrylic-frame prosthesis containing stainless steel screw housings: Palatal view and Underside view.

screw-retained all-acrylic fixed prosthesis was not removed during the initial healing period until such time as master impressions were made for the construction of the definitive prosthesis. Prior to the making of master impressions, all implants were manually and visually evaluated for stability. All mobile implants were removed.

## RESULTS

Of the 552 implants, 544 osseointegrated, for a cumulative survival rate of 98.6% (Table 2). The immediately loaded implant population (522) has a survival rate of 99.0% while the 30 implants placed with the conventional two-stage approach have a survival rate of 90.0%. Two zygomatic implants failed (both due to infection at the implant site), for a 92.9% survival rate.

Three hundred fifteen implants were placed in females; 4 failures occurred in this group (3 implants that had been immediately loaded and 1 implant that was submerged for a healing period), for a 98.8% survival rate. Two of these failed implants were zygomatic implants that became infected; the other two failures were implants placed in soft bone in the posterior regions of the maxilla.

Of the 237 implants placed in males, 4 implants failed to osseointegrate, accounting for a survival rate of 98.3%. Two of the implants that failed had been immediately loaded. Both implants were in the same patient, who admitted to being a heavy smoker (1 pack per day). The other two implants had been placed in extremely soft bone in the pterygomaxillary region, were

submerged, and never osseointegrated. All 55 patients experienced a prosthesis survival rate of 100% for an average of 2.78 years (range, 6 months to 4 years).

## DISCUSSION

In most studies of immediate loading with dental implants,<sup>3,25,26</sup> mandibular arches were treated and maxillary arches were avoided, particularly in the posterior regions, based on historic clinical observations.<sup>27</sup> More recently some reports have indicated success in treating the maxilla with immediate loading protocols,<sup>4,15-22,28-30</sup> including some case reports from the prosthodontist authors of this article.<sup>18,19</sup>

No sinus elevation or sinus grafting was performed for the patients in this study because the literature indicates a higher failure rate for implants placed in sinus-grafted receptor sites.<sup>31</sup> When minimal bone was available beneath the sinus, patients were treated with zygomatic implants, which provided excellent initial stability. Two patients in this study had such minimal bone in the anterior maxilla, requiring shorter implants, that four zygomatic implants were used to provide maximal prosthesis support.<sup>32</sup> Additionally most patients were also treated with pterygomaxillary implants to supplement posterior load distribution and full cross-arch stabilization.

The findings in this study are immediate and functional loading. Once prosthetic adjustments were made, these patients received their immediately loaded prostheses within 1 hour after implant placement. In many previously reported cases dealing with immediate

**TABLE 1** Frequency Distribution of Brånemark Implants in the Maxilla

Size*	Immediately		Immediate Loading	
	Placed	Loaded	Failures	Failures
3.75 × 13 Regular	7	6	0	0
3.75 × 20 Regular	3	1	0	0
4 × 13 Regular	1	1	0	0
4 × 15 Regular	3	3	0	0
5 × 10 Regular	3	2	0	0
5 × 12 Regular	2	2	0	0
3.75 × 8.5 Mk III TiU RP	1	1	0	0
3.75 × 10 Mk III TiU RP	13	10	0	0
3.75 × 13 Mk III TiU RP	46	46	0	0
3.75 × 15 Mk III TiU RP	37	35	0	0
3.75 × 18 Mk III TiU RP	12	12	0	0
4 × 10 Mk III TiU RP	1	1	0	0
4 × 13 Mk III TiU RP	12	12	0	0
4 × 15 Mk III TiU RP	28	27	0	0
4 × 18 Mk III TiU RP	3	3	0	0
4 × 8.5 Mk IV TiU RP	8	5	0	0
4 × 10 Mk IV TiU RP	64	61	0	0
4 × 13 Mk IV TiU RP	94	92	1	1
4 × 15 Mk IV TiU RP	119	111	3	2
4 × 18 Mk IV TiU RP	48	45	2	0
30 Zygomatic	1	1	0	0
35 Zygomatic	7	7	1	1
40 Zygomatic	5	4	0	0
42.5 Zygomatic	6	6	1	1
45 Zygomatic	6	6	0	0
47.5 Zygomatic	1	1	0	0
50 Zygomatic	2	2	0	0
4 × 10 Mk IV Ebon RP	5	5	0	0
4 × 15 Mk IV Ebon RP	11	11	0	0
4 × 18 MK IV Ebon RP	3	3	0	0
Total	552	522	8	5

RP = regular platform; TiU = TiUnite.

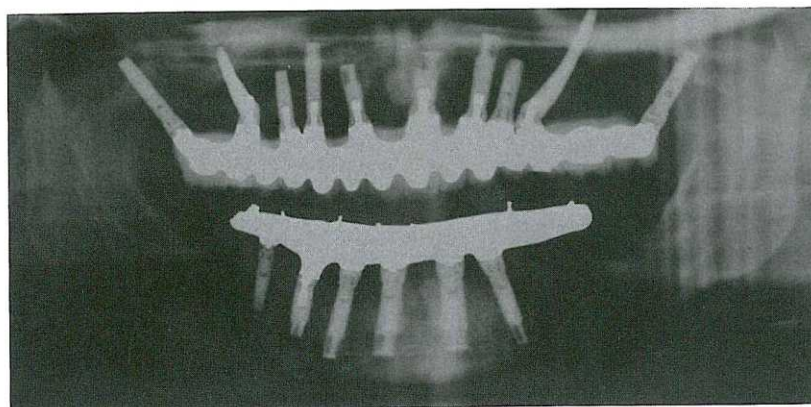
\*In millimeters. Numbers given for zygomatic implants represent length; all diameters are 4 mm.

loading in the maxilla, the implants were loaded early or were short-span prostheses.

Salama and colleagues<sup>28</sup> reported a case in which six implants were placed in the maxilla while applying delayed loading to three of the implants. The loading of the immediately loaded implants occurred at 1 week after placement. Nikellis and colleagues<sup>29</sup> reported an immediate loading study of 85 implants in 14 patients; loading actually occurred 72 hours after implant placement. Olsson and colleagues<sup>30</sup> treated 10 patients with 61 implants that were loaded between 1 and 9 days after placement; these patients received a shorter-span

prosthesis from premolar to premolar. Fischer and Stenberg<sup>33</sup> reported on 95 implants loaded 9 to 18 days after placement with a 100% survival rate. One implant in their study failed prior to the “early” loading.

A study that used submerged implants in conjunction with immediately loaded implants was reported by Tarnow and colleagues.<sup>4</sup> They treated four patients with 43 implants, loading 33 of the 43 implants on the day of placement. Horiuchi and colleagues<sup>20</sup> performed a similar study with five patients who altogether underwent immediate loading of 44 implants in the maxilla on the day of surgery. Some implants were submerged



**Figure 3** Panoramic radiograph illustrating a maxillary definitive prosthesis supported by a combination of zygomatic, pterygomaxillary, and anterior Brånemark System implants.

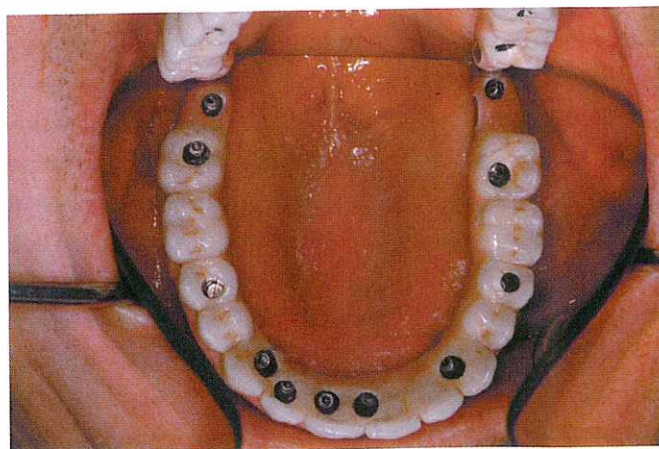
in conjunction with the immediately loaded implants, mainly owing to the poor condition of the implant sites. Kosinski and Skowronski<sup>22</sup> documented a single patient's treatment, reporting full maxillary reconstruction with four immediately loaded implants and six submerged implants. The six nonloaded implants were intended to provide a safety margin for success, following a similar protocol used in the initial prospective study by some of the authors of this report.<sup>12</sup> Kinsel and Lamb<sup>21</sup> treated 14 patients with an average of 7 implants per maxillary arch. At least four of the implants were immediately loaded. Some of these arches had short-span prostheses.

In summary, all of the studies discussed above showed promising results for the immediate and early loading of implants placed in fully edentulous maxillas; a combined total of 429 implants and only 9 failures yielded a survival rate of 97.9%. Only one patient had a prosthesis failure.<sup>30</sup>

In our study, a total of 522 immediately loaded implants were placed in the maxilla with an average of 10 implants per arch and a survival rate of 99.0%. All patients in this study received a full-arch (second molar to second molar) functional screw-retained fixed prosthesis. Critical radiographic evaluation of bone levels were not performed because panoramic radiography does not provide enough detail for such measurements. Patients were randomly evaluated radiographically simply to confirm that marginal bone levels were consistent with previous clinical experience. It is well recognized that bone achieves a stable equilibrium between the first and second thread on the original machined Brånemark implant.<sup>34</sup> No unanticipated or biomechanically significant bone changes were noted

in any of the patients in this study where the majority of the implants were TiUnite implants.

Schnitman and colleagues<sup>25</sup> reported that factors related to the survival of immediately loaded implants include high primary stability, the percentage of implants in contact with cortical bone, the density of cortical bone, and the reduction of micromotion during the healing period. Brunski<sup>35</sup> theorized that 100  $\mu\text{m}$  of micromotion may be the critical threshold above which healing would undergo fibrous repair rather than the desired osseous regeneration, particularly if the micromotion occurs soon after implantation. It is thus believed that the results in this study are so successful because a large number of implants (an average of 10) are spread out throughout the entire arch, which creates a stiff prosthesis, results in little flexure of the material, and controls the forces applied to the bone-implant interface, which appear not to surpass the micromotion threshold introduced by



**Figure 4** Maxillary occlusal view of the definitive prosthesis.

**TABLE 2** Implant Survival Rates

Years	No. of Implants	No. of Failed Implants	Survival Rate (%)	Cumulative Survival Rate (%)
0–1	522	8	98.6	98.6
1–2	361	0	100	98.6
2–3	142	0	100	98.6
3–4	53	0	100	98.6
> 4	45	0	100	98.6

Brunski. With no posterior cantilevers, more favorable loading is applied in those areas where the bone density is less and primary stability may be lower, areas where it has been previously thought that immediate loading should be avoided. The maxilla is a more stable and less deforming osseous environment than the mandible, where mandibular flexure has been theorized to be potentially detrimental to immediate functional loading of full-arch (second-molar) long-span rigidly fixed screw-retained prostheses.<sup>9</sup>

The implants that were immediately loaded in this study were placed and loaded according to the clinician's clinical experience with load distribution, biomechanics, and implant position related to the opposing dentition. Conditions that swayed the clinician's decision to submerge the 30 implants for a period of healing were related to the lack of primary stability of the implants. Implants that were in bone defects (with approximately 75% of the screw threads exposed and requiring substantial autogenous grafting) were often submerged. Other examples included poor bone quality sites with large marrow spaces, short implants placed in soft bone, and implants that were "spinners" (implants that have no apical mobility but continue to rotate in the osteotomy site).

It is highly advantageous for the patient to undergo dental implant treatment via an immediate loading protocol. Immediate loading protocols in the mandible have shown to be comparable to (if not more successful than) the conventional two-stage approach. These data, along with data from many other reports,<sup>4,15–22,36</sup> show the success of osseointegration with immediate loading in the maxilla to be comparable or even superior to that of the two-stage approach. What was therefore originally thought to be a minimum of 4 to 6 months of healing before delivery of a maxillary fixed prosthesis<sup>34</sup> is now reducible to a single visit.

## CONCLUSIONS

The results of this study of full-arch maxillary immediate loading in 55 patients suggest that this protocol is suitable for many patients who would benefit from maxillary implant reconstruction. The 99% implant survival rate and 100% prosthesis survival rate suggest that when the described immediate loading protocol is precisely followed—spreading an average of 10 implants throughout the entire arch and controlling the forces applied to the bone-implant interface by minimizing the flexure of the prosthesis—this protocol is successful in providing a lasting state of osseointegration as the foundation for long-term stability of screw-retained fixed prostheses.

## ACKNOWLEDGMENTS

The authors would like to thank the staff at Prosthodontics Intermedica for their kind and very gentle treatment of the patients; Robert Winkelman and the staff of dental technicians at Fort Washington Dental Lab; Brian Wilson M.D. and Mr. Dan Delaney for anesthesia support; and Dr. Neil Meredith and Dr. Brian Roberts for consultation and insightful recommendations.

## REFERENCES

1. Adell R, Lekholm U, Rockler B, Brånemark P-I. A 15-year study of osseointegrated implants in the treatment of the edentulous jaw. *Int J Oral Surg* 1981; 10:387–416.
2. Schnitman P, Wohrle P, Rubenstein J. Immediate fixed prostheses supported by two-stage threaded implants: methodology and results. *J Oral Implantol* 1990; 16: 96–105.
3. Schnitman P, Wohrle P, Rubenstein J, DaSilva J, Wang N. Ten-year results for Brånemark implants loaded with fixed prostheses at implant placement. *Int J Oral Maxillofac Implants* 1997; 12:495–503.
4. Tarnow D, Emtiaz S, Classi A. Immediate loading of

- threaded implants at stage I surgery in edentulous arches: ten consecutive case reports with 1- to 5-year data. *Int J Oral Maxillofac Implants* 1997; 12:319–324.
5. Chiapasco M, Gatti C, Rossi E, Haefliger W, Markwalder TH. Implant-retained mandibular overdentures with immediate loading: a retrospective multicenter study on 226 consecutive cases. *Clin Oral Implants Res* 1997; 8:48–57.
  6. Brånemark P-I, Engstrand P, Öhrnell L-O, et al. Brånemark Novum: a new treatment concept for rehabilitation of the edentulous mandible. Preliminary results from a prospective clinical follow-up study. *Clin Implant Dent Relat Res* 1999; 1:2–16.
  7. Ericsson I, Randow K, Nilner K, Petersson A. Early functional loading of Brånemark dental implants: 5-year clinical follow-up study. *Clin Oral Implants Res* 2000; 2:70–77.
  8. Gatti C, Haefliger W, Chiapasco M. Implant-retained mandibular overdentures with immediate loading: a prospective study of ITI implants. *Int J Oral Maxillofac Implants* 2000; 15:383–388.
  9. Wolfinger GJ, Balshi TJ, Rangert B. Immediate functional loading of Brånemark system implants in edentulous mandibles: clinical report of the results of developmental and simplified protocols. *Int J Oral Maxillofac Implants* 2003; 18:250–257.
  10. Petropoulos VC, Balshi TJ, Balshi SF, Wolfinger GJ. Treatment of a patient with cleidocranial dysplasia using osseointegrated implants: a patient report. *Int J Oral Maxillofac Implants* 2004; 19:282–287.
  11. Balshi TJ, Wolfinger GJ. A new protocol for immediate functional loading of dental implants. *Dent Today* 2001; 20:60–65.
  12. Balshi T, Wolfinger G. Immediate loading of Brånemark implants in edentulous mandibles: a preliminary report. *Implant Dent* 1997; 6:83–88.
  13. Vidjak F, Zeichner-David M. Immediate-loading dental endosteal implants and the elderly patient. *J Calif Dent Assoc* 2003; 31:917–924.
  14. Balshi TJ, Wolfinger GJ. Immediate placement and implant loading for expedited patient care: a patient report. *Int J Oral Maxillofac Implants* 2002; 17:587–592.
  15. Andersen E, Haanæs HR, Knutsen BM. Immediate loading of single-tooth ITI implants in the anterior maxilla: a prospective 5-year pilot study. *Clin Oral Implants Res* 2002; 13:281–287.
  16. Rocci A, Martignonu M, Gottlow J, Rangert B. Immediate function of single and partial reconstructions in the maxilla using Mk IV fixtures. *Appl Osseointegration Res* 2001; 2:22–26.
  17. Chatzistavrou M, Felton DA, Cooper LF. Immediate loading of dental implants in partially edentulous patients: a clinical report. *J Prosthodont* 2003; 12:26–29.
  18. Balshi TJ, Wolfinger GJ. Immediate loading of dental implants in the edentulous maxilla: case study of a unique protocol. *Int J Periodontics Restorative Dent* 2003; 23:37–45.
  19. Balshi TJ, Wolfinger GJ. Teeth in a Day<sup>®</sup> for the maxilla and mandible: case report. *Clin Implant Dent Relat Res* 2003; 5:11–16.
  20. Horiuchi K, Uchida H, Yamamoto K, Sugimura M. Immediate loading of Brånemark system implants following placement in edentulous patients: a clinical report. *Int J Oral Maxillofac Implants* 2000; 15:824–830.
  21. Kinsel RP, Lamb RE. Development of gingival esthetics in the edentulous patient with immediate loaded, single-stage, implant-supported fixed prostheses: a clinical report. *Int J Oral Maxillofac Implants* 2000; 15:711–721.
  22. Kosinski TF, Skowronski R Jr. Immediate implant loading: a case report. *J Oral Implantol* 2002; 2:87–91.
  23. Balshi TJ. The Biotes conversion prosthesis: a provisional fixed prosthesis supported by osseointegrated titanium fixtures for restoration of the edentulous jaw. *Quintessence Int* 1985; 16:667–677.
  24. Balshi TJ, Wolfinger GJ, Balshi SF. Analysis of 356 pterygo-maxillary implants in edentulous arches for fixed prosthesis anchorage. *Int J Oral Maxillofac Implants* 1999; 14:398–406.
  25. Schnitman PA, Wöhrle PS, Rubenstein JE, DaSilva JD, Koch GG. Implants for partial edentulism. *J Dent Educ* 1988; 52:725–736.
  26. Radnow K, Ericsson I, Nilner K, Petersson A, Glantz P-O. Immediate functional loading of Brånemark dental implants: an 18-month clinical follow-up study. *Clin Oral Implants Res* 1999; 10:8–15.
  27. Jaffin RA, Berman CL. The excessive loss of Brånemark fixtures in type IV bone: a 5-year analysis. *J Periodontol* 1991; 61:2–4.
  28. Salama H, Rose LF, Salama M, Betts NJ. Immediate loading of bilaterally splinted titanium root-form implants in fixed prosthodontics—a technique reexamined: two case reports. *Int J Periodontics Restorative Dent* 1995; 15:345–361.
  29. Nikellis I, Levi A, Nicolopoulos C. Immediate loading of 190 endosseous dental implants: a prospective observational study of 40 patient treatments with up to 2-year data. *Int J Oral Maxillofac Implants* 2004; 19:116–123.
  30. Olsson M, Urde G, Anderson JB, Sennerby L. Early loading of maxillary fixed cross-arch dental prostheses supported by six or eight oxidized titanium implants: results after 1 year of loading, case series. *Clin Implant Dent Relat Res* 2003; 5(Suppl 1):81–87.
  31. Jensen OT, Shulman LB, Block MS, Iacono VJ. Report of the Sinus Consensus Conference of 1996. *Int J Oral Maxillofac Implants* 1998; 13 Suppl:11–45.
  32. Balshi TJ, Wolfinger GJ, Petropoulos VC. Quadruple zygomatic implant support for retreatment of resorbed iliac crest bone graft transplant. *Implant Dent* 2003; 12:47–53.
  33. Fischer K, Stenberg T. Early loading of ITI implants



- supporting a maxillary full-arch prosthesis: 1-year data of a prospective, randomized study. *Int J Oral Maxillofac Implants* 2004; 19:374–381.
34. Brånemark P-I, Zarb GA, Albrektsson T, editors. *Tissue integrated prosthesis. Osseointegration in clinical dentistry.* Chicago, IL: Quintessence Publishing Co., 1985.
35. Brunski JB. Avoid pitfalls of overloading and micromotion of intraosseous implants. *Dent Implantol Update* 1993; 4:77–81. (Interview)
36. Rocci A, Martignoni M, Gottlow J. Immediate loading in the maxilla using flapless surgery, implants placed in predetermined positions, and prefabricated provisional restorations: a retrospective 3-year clinical study. *Clin Implant Dent Relat Res* 2003; 5(Suppl 1):29–36.