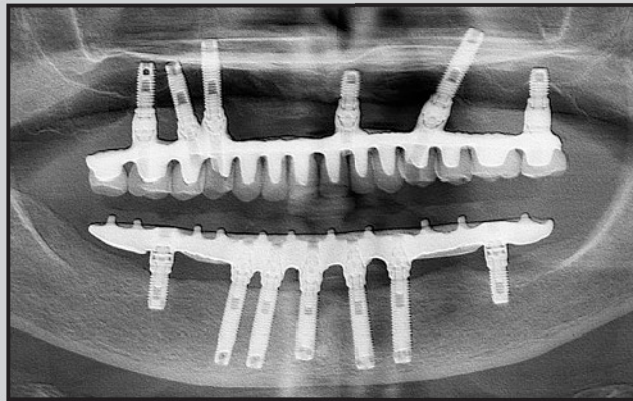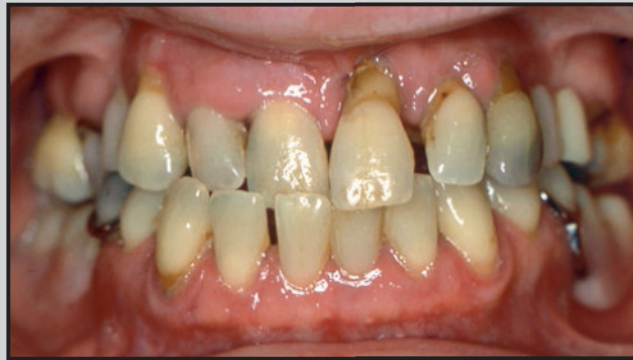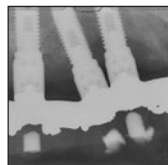


Thirty-Two-Year Success of Dental Implants in Periodontally Compromised Dentition



Thomas J. Balshi, DDS, PhD, FACP¹

Glenn J. Wolfinger, DMD, FACP²

Stephen F. Balshi, MBE³

Myron Nevins, DDS⁴

David M. Kim, DDS, DMSc⁵

Osseointegrated dental implants have become an integral factor in the replacement of missing teeth. These implants have demonstrated long-term success for periodontally compromised patients, who require a high level of success to maintain a sense of optimism. This case report offers 32-year results of implant treatment in the maxilla and 25-year results in the mandible. Some maxillary implants suffered a few threads of bone loss, but all seven mandibular implants met Albrektsson's definition of success after 25 years. The purpose of this case report is to provide evidence that further supports the findings of osseointegrated implant treatment's longevity and success, as reported in other studies. Int J Periodontics Restorative Dent 2018;38:827–831. doi: 10.11607/prd.3709

The success of osseointegration has changed modern dental treatment planning and continues to offer predictable results to most patients.^{1–5} As peri-implantitis becomes more common, success rates for its treatment have become more reliable and show an accuracy comparable to established treatment modalities in other disciplines. Some authors have targeted smoking and a history of periodontitis as significant risk factors, which may cause concern for patients who inquire about the longevity and success of implant prosthodontics. However, many osseointegration studies result in long-term success, including two studies^{6,10} that reported successful results in refractory peri-implantitis patients, ie, those who do not respond appropriately to therapy.^{6–17}

The purpose of this article is to report the long-term results of osseointegration in a patient with advanced periodontal disease. Following initiation of the patient's dental implant therapy in 1984, she also received appropriate maintenance therapy after implant and prosthesis placement in 1986 to 1988. The patient's maxillary implant rehabilitation was published in 1988.⁴ The implants were loaded and in full function for 32 years, though the maxillary prosthesis was remade in 2012. In 1993, the fixed prosthesis in the mandible was changed to a fully implant-

¹Founder and Prosthodontist, PI Dental Center, Institute for Facial Esthetics, Fort Washington, Pennsylvania, USA; Part-Time Clinical Professor, Implant Prosthodontics, Nova Southeastern University, Fort Lauderdale, Florida, USA.

²President, PI Dental Center, Fort Washington, Pennsylvania, USA.

³President, CM Prosthetics Dental Laboratory, Fort Washington, Pennsylvania, USA.

⁴Part-Time Associate Professor, Division of Periodontology, Department of Oral Medicine, Infection and Immunity, Harvard School of Dental Medicine, Boston, Massachusetts, USA.

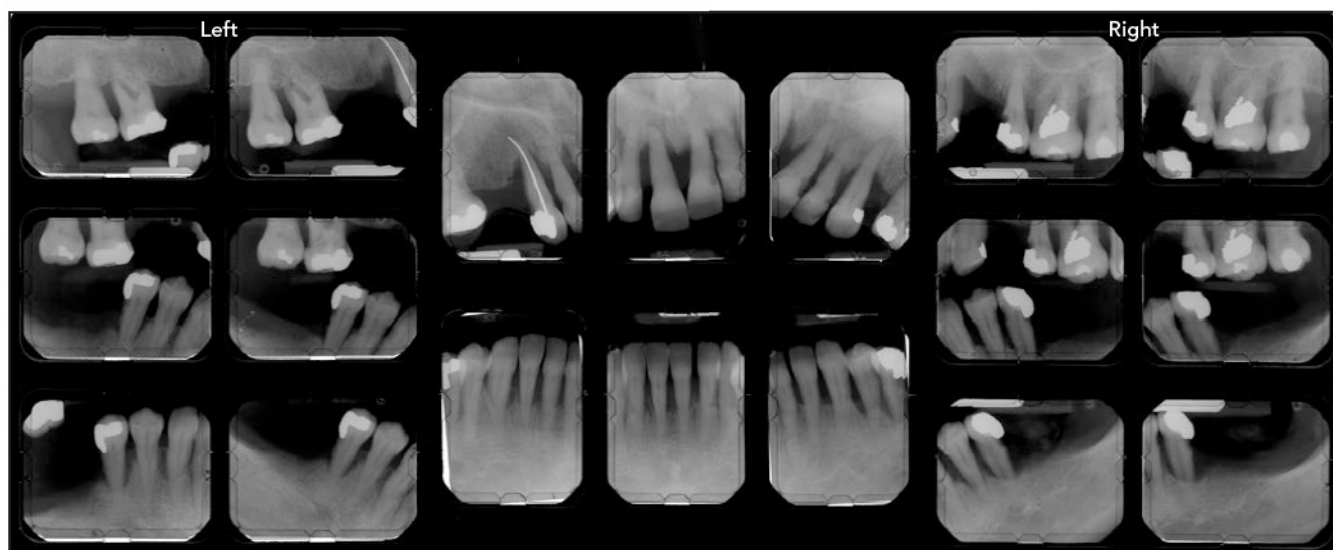
⁵Associate Professor, Division of Periodontology, Department of Oral Medicine, Infection and Immunity, Harvard School of Dental Medicine, Boston, Massachusetts, USA.

Correspondence to: Dr Myron Nevins, Division of Periodontology, Department of Oral Medicine, Infection and Immunity, Harvard School of Dental Medicine, 188 Longwood Ave, Boston, MA 02115, USA. Email: nevinsperimp@aol.com

©2018 by Quintessence Publishing Co Inc.

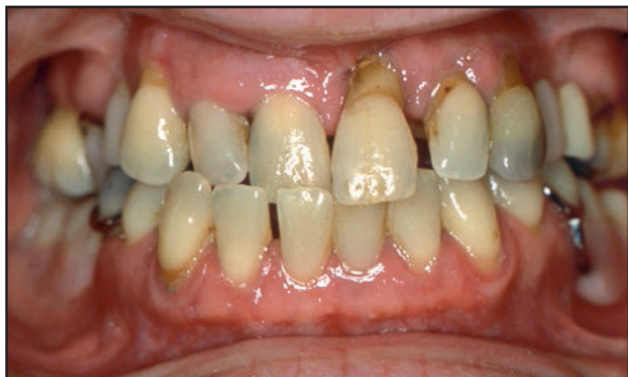

Fig 1 A 55-year-old patient presented with advanced periodontal disease in both arches in 1984.



supported prosthesis, which has serviced the patient for 25 years. The fixed mandibular screw-retained, implant-supported prosthesis underwent a complete change in 2012 due to a fracture in the cast-precious metal frame. The new prosthesis consisted of a robotically milled titanium frame and an AvaDent resin-veneer dentition.

Case Report

In 1984, a 55-year-old patient presented with a chief complaint of poor esthetics. The patient was in

good health but suffered advanced periodontal disease with an anterior crossbite and extruded, drifted, and missing teeth. Radiographic examination revealed advanced bone loss that was evident throughout the maxillary arch, and moderate to advanced bone loss was present throughout the patient's remaining mandibular dentition (Fig 1). Close inspection of the radiographs also indicated that the remaining maxillary molar dentition had been severely compromised by bone loss and furcation complications. These teeth had questionable to hopeless prognoses.

During the first phase of treatment, presurgical prosthodontic care required immediate stabilization of the maxillary dentition with a heat-processed acrylic-resin provisional restoration. Limited orthodontic tooth movement was necessary to realign the remaining mandibular dentition prior to its provisionalization. Periodontal therapy was then performed to determine the feasibility of maintaining some of the maxillary abutment teeth.

A fixed provisional partial denture was fabricated for each arch. The mandibular teeth were to be retained and restored using crowns

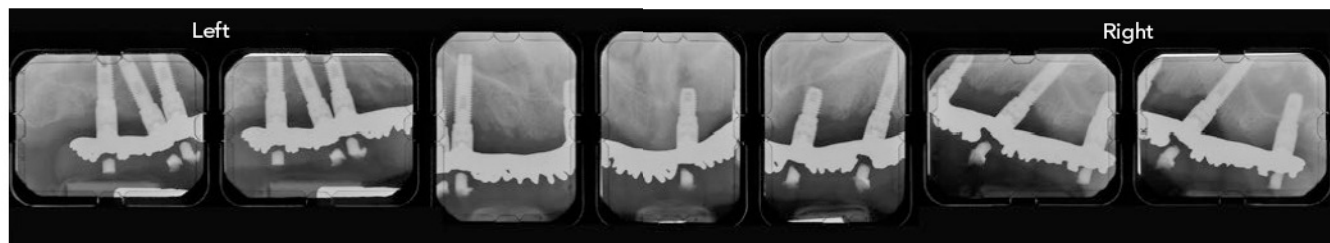
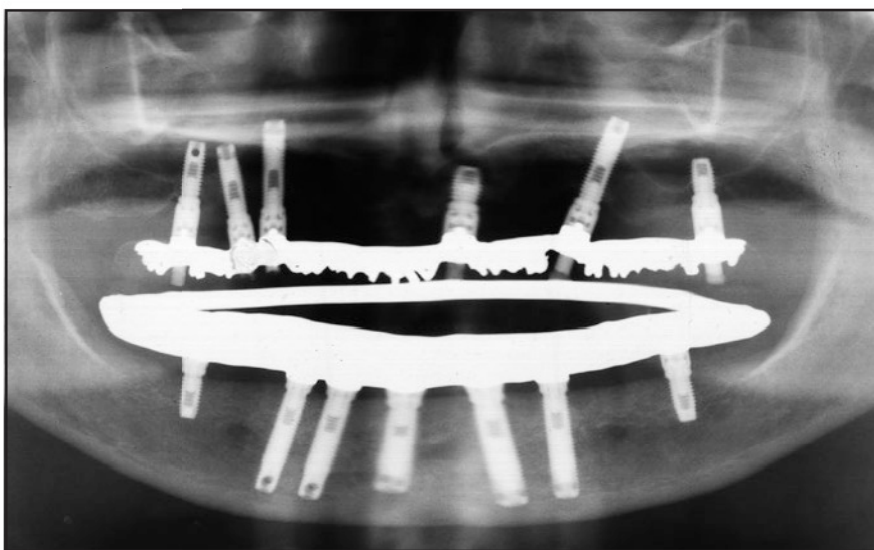


Fig 2 Maxillary teeth were removed, and the final maxillary prosthesis (supported by six implants) was loaded in 1986.

Fig 3 Remaining mandibular teeth were removed, and a fixed prosthesis (supported by seven implants) was fabricated and loaded in 1993.



and a posterior removable prosthesis. Four maxillary teeth were prepared to accept the provisional restoration, allowing the implants to be placed and the patient to avoid the use of a complete removable denture, thereby maintaining her self-esteem. These four teeth were later extracted when the maxillary implants (six total) were ready to be loaded with the final prosthesis in 1986 (Fig 2). This prosthesis consisted of a rigid cast-gold framework with modified denture teeth applied. The patient expressed her satisfaction with the screw-retained implant-supported prosthesis. In

1993, the mandible received 7 implants and a fixed prosthesis, and these implants have served the patient for 25 years (Fig 3).

In 2010, 24 years following the initial maxillary implant prosthodontic rehabilitation, the patient presented to her prosthodontist, who noted significant wear of both the maxillary and mandibular resin-veneered prostheses. At that time, the patient was reluctant to proceed with the recommendations that new prostheses be constructed. Two years later, in July 2012, the patient presented with additional wear on both prostheses, a fractured denture tooth

(maxillary left second premolar), and a crack in the mandibular cantilever casting. Following a discussion regarding overall wear and the loss of occlusal vertical dimension (OVD), the patient agreed to proceed with the construction of new prostheses for both the maxilla and mandible.

At that same visit, the original abutments were removed and an implant-level impression was made. Master casts were cross-articulated with stone casts of the original conversion prostheses that had recorded and maintained the original OVD. Shorter multiunit abutments were inserted on the master cast, and the

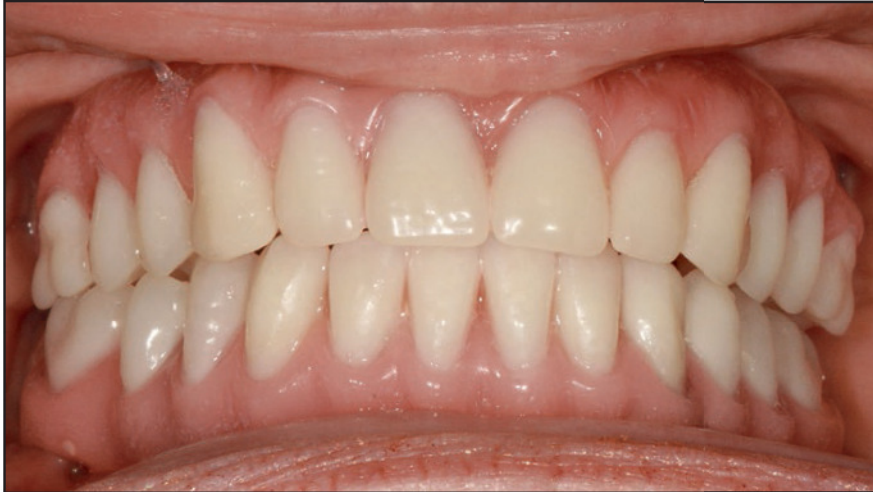

Fig 4 In 2012, both maxillary and mandibular prostheses were replaced with new ones due to significant wear. The maxilla was restored with a unit-built restoration comprised of milled titanium framework, individual lithium disilicate crowns, and a custom acrylic-resin veneer. The mandible was restored with traditional denture teeth processed onto a milled titanium framework using the same custom acrylic-resin gingival veneer as the maxilla.

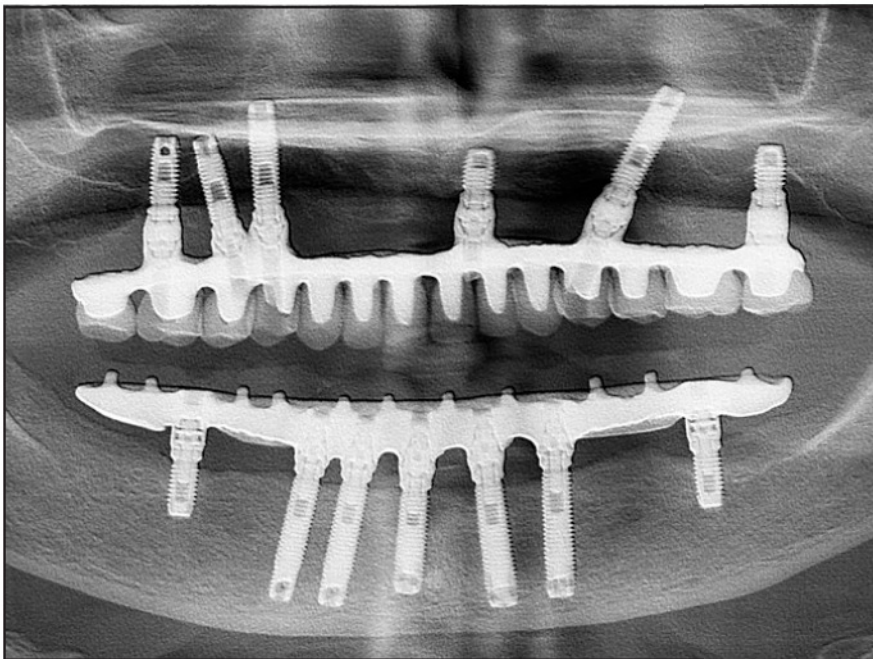


Fig 5 Latest panoramic radiograph shows stability of the bone level around dental implants.

maxillary prosthesis was designed. The framework was constructed to support individual ceramic crowns, which were cemented to the frame

with resin cement. A polymethyl methacrylate (PMMA) gingival resin was then processed to provide appropriate contours and esthetics.

The mandibular prosthesis was designed to be a classic hybrid with resin denture teeth. Unlike the original full-mouth reconstruction where PMMA was used in both arches, the new design placed ceramic teeth in the maxilla and resin denture teeth in the mandible. This design reduces the wear to only the mandibular arch, leaving the ceramic teeth in the maxilla in a static position. This prosthodontic configuration is proven to be beneficial to the patient, as it reduces the costs of retreats.⁵

The original abutments were reinserted and the resin-veneered prostheses replaced. The patient then returned in October 2012 for the delivery of the new multiunit abutments and the new maxillary and mandibular prostheses (Fig 4). A panoramic radiograph was made to evaluate both the seating of the prostheses and the bone levels following delivery.

The design of the maxillary prosthesis has since been completely digitized by Global Dental Science and robotically milled with the AvaDent AccelerSet reconstructive system. Future retreats of the mandibular arch will be accomplished with a fully milled PMMA from AvaDent, avoiding the use of individual denture teeth, making the full-arch reconstruction much stronger and longer lasting.

Conclusions

The 6 years following construction and delivery of the new prostheses in 2012 have been uneventful, and the patient continues to function ef-

fectively with stable bone-anchored prostheses, supported by original Brånemark machined-surface implants in both arches. Once again, there is evidence of a successful long-term benefit for a periodontally compromised patient (Fig 5).

Acknowledgments

The authors of this study would like to thank CM Prosthetics Laboratory, Fort Washington, for the 2012 design and construction of prostheses. The authors report no conflicts of interest.

References

1. Bahat O. Brånemark system implants in the posterior maxilla: Clinical study of 660 implants followed for 5 to 12 years. *Int J Oral Maxillofac Implants* 2000; 15:646–653.
2. Attard NJ, Zarb GA. Long-term treatment outcomes in edentulous patients with implant overdentures: The Toronto study. *Int J Prosthodont* 2004;17:425–433.
3. Ortorp A, Jemt T. Clinical experiences with laser-welded titanium frameworks supported by implants in the edentulous mandible: A 10-year follow-up study. *Clin Implant Dent Relat Res* 2006;8:198–209.
4. Balshi TJ. Converting patients with periodontally hopeless teeth to osseointegration prostheses. *Int J Periodontics Restorative Dent* 1988;8:8–33.
5. Balshi TJ, Wolfinger GJ, Alfano SG, Balshi SF. The retreat: A definition and retrospective analysis of 205 implant-supported fixed prostheses. *Int J Prosthodont* 2016;29:126–131.
6. Nevins M, Langer B. The successful use of osseointegrated implants for the treatment of the recalcitrant periodontal patient. *J Periodontol* 1995;66:150–157.
7. Nevins M. Will implants survive well in patients with a history of inflammatory periodontal disease? *J Periodontol* 2001; 72:113–117.
8. Nevins M, Uzel NG, Kim DM. The safety and efficacy of dental implants for periodontally compromised patients: A review of current knowledge. *Dent Implantol Update* 2009;20:81–87.
9. Nevins M, Kim DM. Classical versus contemporary treatment planning for aggressive periodontal disease. *J Periodontol* 2010;8:767–775.
10. Simion M, Nevins M, Rasperini G, Tironi F. A 13- to 32-year retrospective study of bone stability for machined dental implants. *Int J Periodontics Restorative Dent* 2018;38:489–493.
11. Stacchi C, Berton F, Perinetti G, et al. Risk factors for peri-implantitis: Effect of history of periodontal disease and smoking habits. A systematic review and meta-analysis. *J Oral Maxillofac Res* 2016;7:e3.
12. Monje A, Aranda L, Diaz KT, et al. Impact of maintenance therapy for the prevention of peri-implant diseases: A systematic review and meta-analysis. *J Dent Res* 2016;95:372–379.
13. Monje A, Wang HL, Nart J. Association of preventive maintenance therapy compliance and peri-implant diseases: A cross-sectional study. *J Periodontol* 2017;88:1030–1041.
14. Albrektsson T, Canullo L, Cochran D, De Bruyn H. "Peri-Implantitis": A complication of a foreign body or a man-made "disease". Facts and fiction. *Clin Implant Dent Relat Res* 2016;18:840–849.
15. Hasegawa T, Kawabata S, Takeda D, et al. Survival of Brånemark System Mk III implants and analysis of risk factors associated with implant failure. *Int J Oral Maxillofac Surg* 2017;46:267–273.
16. Jemt T, Karouni M, Abitbol J, Zouiten O, Antoun H. A retrospective study on 1592 consecutively performed operations in one private referral clinic. Part II: Peri-implantitis and implant failures. *Clin Implant Dent Relat Res* 2017;19:413–422.
17. Correia F, Gouveia S, Felino AC, Costa AL, Almeida RF. Survival rate of dental implants in patients with history of periodontal disease: A retrospective cohort study. *Int J Oral Maxillofac Implants* 2017;32:927–934.