

---

# Analysis of 356 Pterygomaxillary Implants in Edentulous Arches for Fixed Prosthesis Anchorage

Thomas J. Balshi, DDS\*/Glenn J. Wolfinger, DMD\*\*/Stephen F. Balshi II\*\*\*

One thousand eight hundred seventeen implants were placed in the completely edentulous maxillae of 189 patients (122 female; 67 male). The patients' mean age was 60 years (range 28 to 91 years). Three hundred fifty-six of the 1,817 implants were placed in the pterygomaxillary area, and all patients were restored with complete-arch fixed detachable prostheses. The mean number of implants per maxillary prosthesis was 9.0 (range 6 to 15). During stage II surgery and before loading, 41 pterygomaxillary implants (11.5%) were not osseointegrated and were removed. After a mean loading period of 4.68 years (range 0.06 to 9.20 years), 1 additional pterygomaxillary implant was lost. Altogether, 42 of 356 pterygomaxillary implants (11.8%) were removed. Survival rates according to implant size, bone quality, and tooth position were also recorded. This study illustrates a cumulative survival rate of 88.2% for pterygomaxillary site implant placement in edentulous maxillary arches.

(INT J ORAL MAXILLOFAC IMPLANTS 1999;14:398-406)

**Key words:** Brånemark implants, complete-arch fixed detachable prostheses, osseointegration, pterygomaxillary, survival rate, tuberosity

---

The Brånemark System has demonstrated high success rates for implants placed in completely edentulous jaws since its introduction to clinical dentistry in 1965.<sup>1</sup> Adell and coworkers<sup>2</sup> demonstrated 15 years of functional and successful results in the treatment of edentulous jaws; however, the majority of implants in the maxilla were placed anterior to the maxillary antrum. Other researchers have also documented the success of the Brånemark implant system.<sup>3-6</sup> According to Zarb et al,<sup>7</sup> the posterior maxilla is the most difficult and problematic intraoral area for treatment with osseointegrated implants.

The anatomy of the maxillary posterior quadrant presents many limitations to implant placement. These anatomic factors include poor bone quality and decreased bone quantity,<sup>8</sup> location of the antrum,<sup>9</sup> and accessibility of the area,<sup>10</sup> especially in the pterygomaxillary region. It was previously thought that the pterygomaxillary area was inoperable and not suited for implants because of large fatty marrow spaces, limited trabecular bone, and the rare presence of cortical bone covering the alveolus. Because of these anatomic factors and some biomechanical factors,<sup>11</sup> one would expect the success rate for implants placed into the posterior maxilla to be lower than that for other locations. In 1991, Reiger<sup>12</sup> recommended using a larger number of implants in the posterior maxilla to compensate for the decreased predictability for osseointegration in that area. Langer et al<sup>13</sup> recommended the use of wider diameter implants to obtain a greater surface area for bone contact.

Bone-graft procedures, such as sinus lifts and onlay grafts, were also introduced to address some of these anatomic conditions, but these procedures require a longer healing period and may present other complications.<sup>14-18</sup> In addition, there is a risk of morbidity at the donor site with autogenous bone grafting procedures. Jaffin and Berman<sup>19</sup> reported on implants used specifically in

---

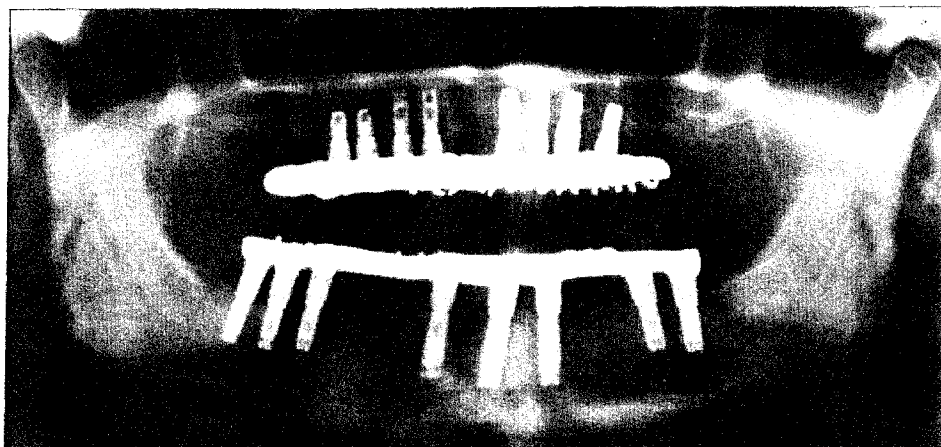
\*Research and Private Practice, Institute for Facial Esthetics, Prosthodontics Intermedica, Fort Washington, Pennsylvania.

\*\*Research and Private Practice, Institute for Facial Esthetics, Prosthodontics Intermedica, Fort Washington, Pennsylvania; and Staff Prosthodontist, VA Medical Center, Philadelphia, Pennsylvania.


\*\*\*Bone and Implant Research, Institute for Facial Esthetics, Fort Washington, Pennsylvania; and Student, Biomedical Engineering Program, The Catholic University of America, Washington, D.C.

**Reprint requests:** Dr Thomas J. Balshi, Prosthodontics Intermedica, 467 Pennsylvania Avenue #201, Fort Washington, PA 19034. Fax: 215-643-1149.

**Fig 1a** Panoramic radiograph of a maxillary implant prosthesis supported by short, posterior implants and functionally overloaded by posterior cantilevers.



**Fig 1b** Periapical radiographs show the loss of osseointegration of the 2 posterior left implants and 1 posterior right implant.



the maxillary posterior and noted a higher failure rate related to Type IV bone. Schnitman<sup>20</sup> demonstrated that the posterior maxilla was the least successful area for osseointegration to occur. In his report, only 72% of implants placed in the posterior maxilla achieved osseointegration.

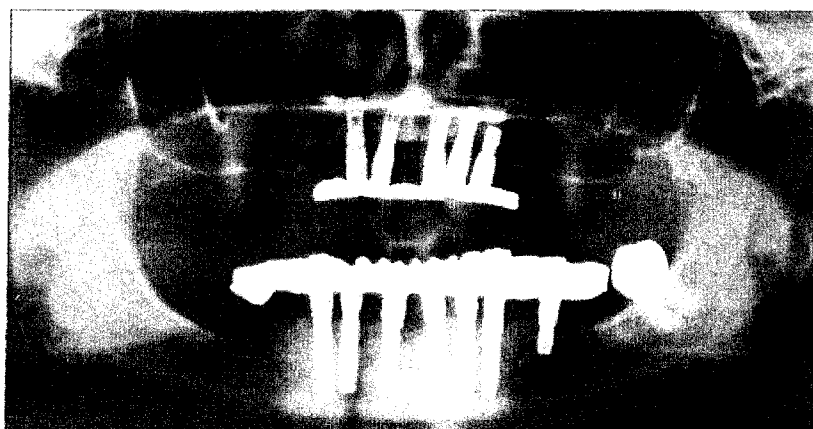
Force factors are another variable affecting the long-term stability of implants, particularly in the posterior region.<sup>21</sup> The magnitude of occlusal load is larger in the molar region than in the anterior region. Masticatory forces of 155 N have been reported in the incisor region, with comparative forces of 288 N and 565 N in the premolar and molar regions, respectively.<sup>22</sup> In parafunction, these forces can be as much as 3 times the normal masticatory forces,<sup>23-25</sup> which would apply significant stress to the bone-implant interface and the component hardware.

Posterior cantilevers on implant prostheses produce complications, including screw fracture, prosthesis fracture, bone loss, and loss of osseointegration<sup>26</sup> (Fig 1). Improving biomechanical stability and load distribution by means of noncantilevered, bone-anchored restorations should enhance the long-term prognosis of implant restorations in the posterior maxilla.<sup>27,28</sup> The option of using fewer implants for an overdenture in the maxilla does not alleviate the psychologic problems associated with a detachable prosthesis. In addition, maxillary overdentures in general have demonstrated

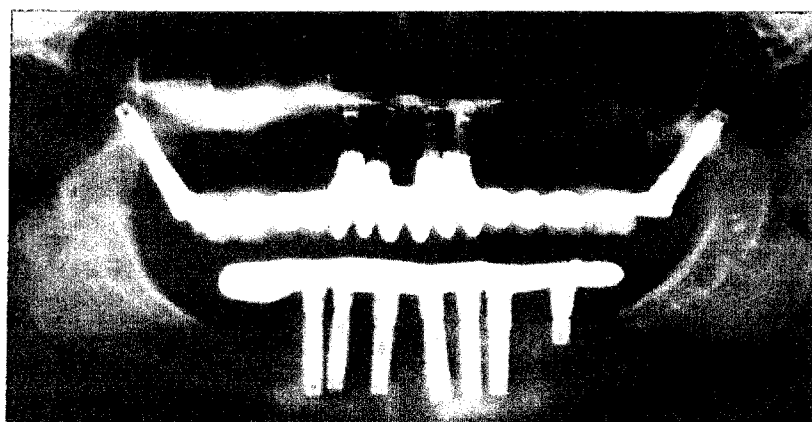
poorer success rates for both the implants (72.4%) and for prostheses (77.9%).<sup>29</sup> And while the initial cost of an implant overdenture that uses fewer implants may be less than that of a fixed removable prosthesis, long-term maintenance costs may nearly double the overall cost for treatment because of the need for denture relines and replacement of worn attachments.<sup>29</sup>

If implants are placed in the compact bone of the pterygomaxillary plate<sup>30</sup> and successfully osseointegrate (Fig 2), they can provide support and retention for implant restorations and eliminate posterior cantilevers, which may occur when using only anterior implants to support a full complement of teeth in a complete-arch restoration. Placement of implants in the pterygomaxillary region provides posterior bone support without sinus augmentation or supplemental grafts. Because of limited accessibility, placement of these implants is more technically demanding than placing implants anterior to the antrum. However, there are no greater risks associated with implant placement in this area.

The intention of this study was to examine all the patients in a private clinic whose dentition had been restored with a complete fixed maxillary prosthesis supported by Brånemark implants in pterygomaxillary sites. This retrospective analysis addresses the biomechanical aspects of implant size, position, and bone quality with patient age, gender, smoking habits, and medications.



**Fig 2a** Maxillary right antrum enlarged, with little crestal bone available for conventional implant placement.



**Fig 2b** Bilateral pterygomaxillary implants. At 2 years postoperative, they successfully engaged the compact bone for stabilization at stage I, leading to osseointegration years later.

**Materials and Methods**

Brånemark System implants (Nobel Biocare AB, Göteborg, Sweden) were utilized following the strict surgical and prosthodontic protocol recommended by the manufacturer. This study included all patients whose treatment was planned and carried out in a private clinic (Prosthodontics Intermedica, Fort Washington, PA) for a complete fixed detachable implant restoration involving implants in the pterygomaxillary region. The criteria for surgically placing implants in the pterygomaxillary area depended on a sufficient quantity of bone in the area. Patient selection followed the same protocol as for placement in other areas and included the patient's ability to tolerate a minor surgical procedure. Ninety-seven percent of the opposing dentitions were restored with ceramometal fixed partial dentures or hybrid (gold bar with acrylic denture teeth) fixed detachable implant-supported prostheses. A total of 1,817 implants were placed in the maxillae of 189 patients (122 females, 67 males) with an average age of 60 years (range 28 to 91 years). Of these 1,817

implants, 356 were placed in pterygomaxillary sites. Abutments were connected after a minimum of 5 to 6 months of undisturbed healing.

Table 1 shows the types of Brånemark implants used in edentulous maxillae. Implant selection was based on the anatomic factors of each individual osteotomy site, including bone quantity and quality, with an attempt to maximize the surface area and primary stability of each individual implant. A variety of implant types were used in the pterygomaxillary region the most common implant being 15 mm long and 3.75 mm in diameter. Standard-diameter implants (3.75 mm) were used more frequently, while wider-diameter implants (4.0 mm and 5.0 mm) and self-tapping implants were placed in fewer patients.

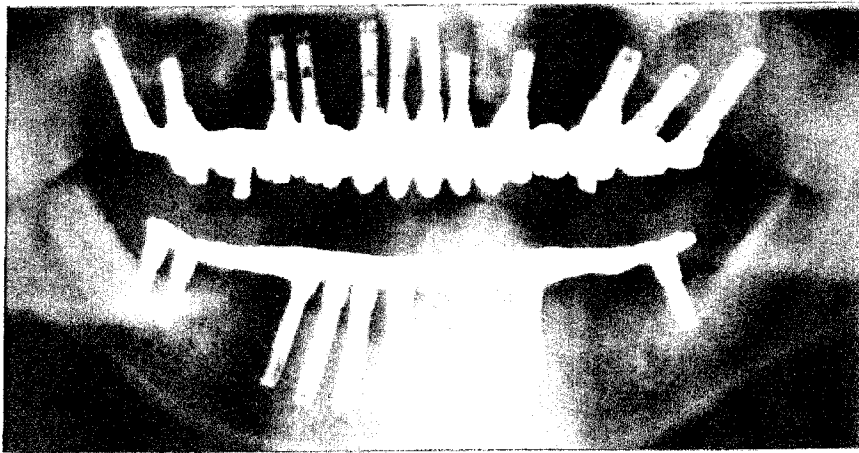
Table 2 illustrates the distribution of abutment types. Standard abutments were routinely used on the mesially inclined pterygomaxillary implants to accommodate implant inclination and the path of insertion of the restorations. A mean abutment length of 4.4 mm (range 3 to 7 mm) was required because of generally thicker mucosa in this area.

**Table 1** Frequency Distribution of Implant Design in Maxilla and Pterygomaxillary Sites

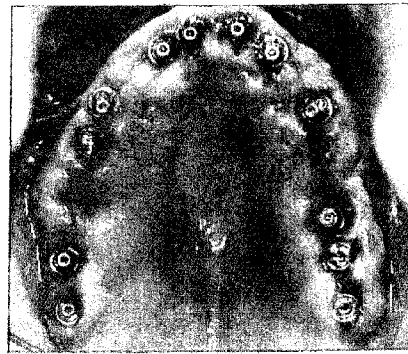
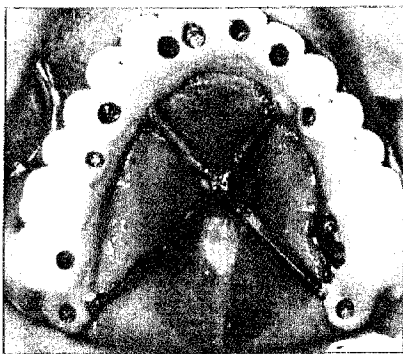
Implant dimensions	Total no. of maxillary implants	No. of pterygomaxillary site implants
Standard (3.75-mm-diameter)		
7 mm long	7	0
8.5 mm long	13	1
10 mm long	281	7
13 mm long	505	42
15 mm long	531	190
18 mm long	131	37
20 mm long	38	21
Self-tapping (3.75-mm-diameter)		
10 mm long	2	0
13 mm long	20	2
15 mm long	17	5
18 mm long	7	4
4-mm-diameter		
7 mm long	3	0
8.5 mm long	2	0
10 mm long	57	3
13 mm long	31	2
15 mm long	48	24
18 mm long	30	14
5-mm-diameter		
6 mm long	7	1
8 mm long	24	0
10 mm long	46	1
12 mm long	13	2
Wide-platform (5-mm-diameter)		
10 mm long	1	0
13 mm long	3	0
Total	1817	356

**Table 2** Distribution of Abutment Types

Abutment dimensions (mm)	Total no. of maxillary abutments	No. of pterygomaxillary site abutments
Regular		
3.0	223	90
4.0	147	98
5.5	116	93
7.0	27	23
8.5	5	3
EsthetiCone		
1.0	286	2
2.0	128	0
3.0	41	1
MirusCone		
1.0	7	0
2.0	1	0
3.0	1	0
Angulated		
30 degrees	362	3
17 degrees 2.0	165	0
17 degrees 3.0	20	1
CeraOne		
1.0	7	0
2.0	1	0
UCLA	4	0
Total	1541	314

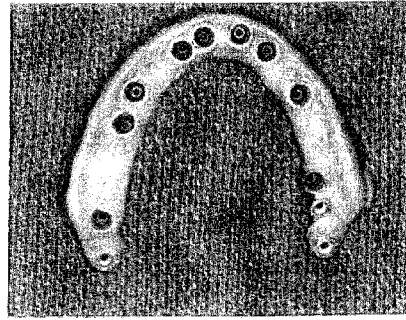
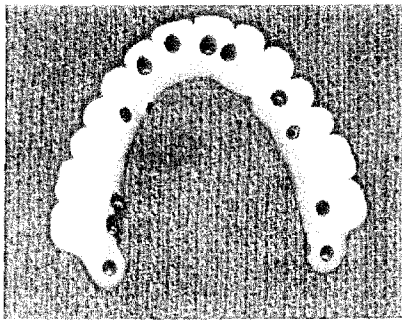


**Fig 3a** Panoramic radiograph illustrates bilateral pterygomaxillary implants supporting a fixed prosthesis.



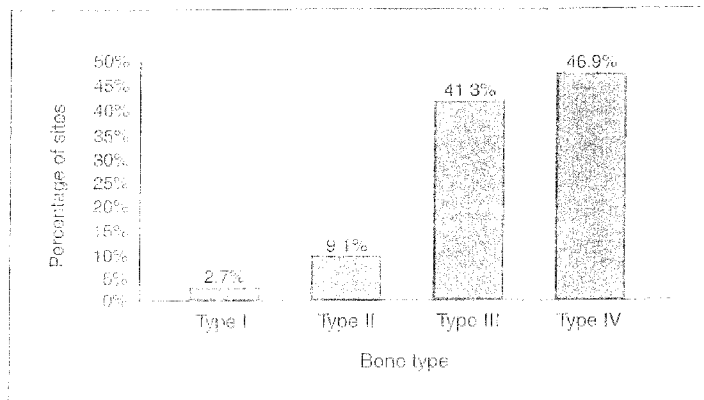
**Fig 3b** (Left) Metal-ceramic fixed (screw-retained) maxillary prosthesis with bilateral pterygoid implant support. Cross-arch stabilization bars are retained until porcelain firing is complete.

**Fig 3c** (Right) Bilateral pterygomaxillary implants 2 weeks after abutment connection.



**Fig 3d** (Left) Palatal view, prior to placement, of metal-ceramic screw-retained fixed prosthesis supported by pterygoid implants.

**Fig 3e** (Right) View of tissue surface side of metal-ceramic screw-retained fixed prosthesis.



**Fig 4** Breakdown of bone types seen in pterygomaxillary sites.

**Table 3** Survival Rates According to Implant Size

Implant dimensions (mm)	No. of pterygomaxillary implants placed	No. of pterygomaxillary implants integrated	Survival rates (%)
Standard (3.75-mm-diameter)			
8.5 mm long	1	1	100.0
10 mm long	7	4	57.1
13 mm long	42	35	83.3
15 mm long	190	172	90.6
18 mm long	37	32	86.5
20 mm long	21	18	85.7
Self-tapping (3.75-mm-diameter)			
13 mm long	2	2	100.0
15 mm long	5	5	100.0
18 mm long	4	4	100.0
4-mm-diameter			
10 mm long	3	3	100.0
13 mm long	2	1	50.0
15 mm long	24	21	87.5
18 mm long	14	12	85.7
5-mm-diameter			
6 mm long	1	1	100.0
10 mm long	1	1	100.0
12 mm long	2	2	100.0
Total	356	314	88.2

The majority of the maxillary bone-anchored prostheses (89.4%) were metal-ceramic restorations (Fig 3). Some prostheses (10.6%) utilized the original Brånemark design,<sup>1</sup> a hybrid fixed detachable implant restoration using a gold bar substructure with acrylic resin denture teeth. The mean number of implants per prosthesis was 9.0 (range 5 to 15). The rationale for placement of 8 or more implants to support a fixed complete-arch prosthesis in the maxilla is supported by Kopp's analysis of various studies on implant restorative predictabilities.<sup>31</sup>

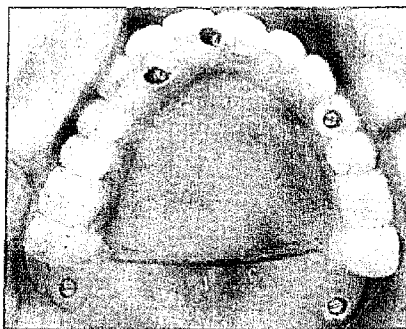
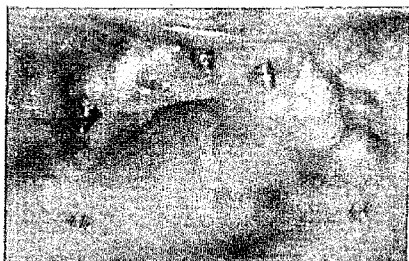Corresponding to the classification of Lekholm and Zarb,<sup>32</sup> the quality of jaw bone was subjectively graded in 4 groups by the amount of compact bone and the density of trabecular bone. One operator recorded the bone quality of all patients at the time of implant placement. Figure 4 shows the percentages of various bone qualities encountered during implant placement. Type IV bone was most frequently encountered. The survival of each implant was evaluated at the time of abutment connection by means of a mobility test. Following placement of prostheses, survival was evaluated by means of marginal bone maintenance, as seen on panoramic radiographs, and absence of pain or symptoms of infection.

## Results

The cumulative survival rate of implants in the pterygomaxillary area was 88.2% after an average functional period of 4.68 years. Of the 356 implants placed in pterygomaxillary sites, 314 (88.2%) were osseointegrated. The interval survival rates were 88.5% at stage II and 99.7% after stage II. This takes into account 41 failed implants at stage II (11.5%) and the loss of 1 implant following loading (11.8%). Five patients died of natural causes following prosthesis placement, with successful use of the prostheses during the period of function (average 4.4 years; range 2.0 to 6.4 years).

Sixteen different implant types were used in pterygomaxillary sites, including standard, self-tapping, and wide-diameter implants. The survival rate for each implant type in pterygomaxillary sites is illustrated in Table 3.

Bone quality was subjectively recorded for each of the 356 implants placed in the pterygomaxillary area. Two of the 356 implants were placed in Type I bone, and both integrated (100.0%). Six implants were placed in Type II bone, and 4 integrated (66.6%); some required conventional bone-tapping during placement. One hundred fifteen of 131 implants integrated in



**Fig 5a** (Left) Clinical view of the bilateral pterygomaxillary implants with the abutments connected.

**Fig 5b** (Right) View of the cross-arch stabilization bars.

Type III bone (87.8%), where bone tapping was not required. The remaining 217 implants were placed in Type IV bone, with no bone tapping, and 193 integrated (88.9%).

In this analysis, 189 patients were treated with implants placed in pterygomaxillary sites. Forty patients (25 females, 15 males) experienced implant failure. Two of the 15 males had both pterygomaxillary implants fail. The average age of the patients with failed implants was 59.2 years (range 30 to 91 years). Of the patients with failed implants, four female patients and 3 male patients were smokers. Smoking was foreseen to be a negative factor with osseointegration.

Eight different types of implants failed in the pterygomaxillary area. The largest number of failed implants (18) were 15 mm long and 3.75 mm wide. However, that size was also the most frequently placed implant (190) and yielded a 90.6% cumulative survival rate. Seven implants that were 10 mm long and 3.75 mm wide failed, and 5 implants that were 18 mm long and 3.75 mm wide failed. All other implant types had 3 or fewer failures (Table 3).

In reviewing the general health of the patients, 20 patients who experienced failures in the pterygomaxillary area were not taking any medications, 6 patients took aspirin regularly, 2 patients were on Prozac, and 1 patient was on estrogen supplements. None of the 3 patients who had undergone chemotherapy or radiation treatment had failures; however, radiation was not focused on the implant areas.

### Discussion

The bone surrounding implants that are placed in the posterior maxilla may be inferior in quality, especially in the premolar or molar region.<sup>19</sup> A distinct advantage of placing implants in the pterygo-

maxillary region is the ability to provide bone anchorage in the posterior maxilla without sinus augmentation, supplemental grafting, or the possibility of, and the detrimental effects of, cantilevered loading forces. Engaging the cortical bone of the pterygoid plate with long implants can enhance initial stability and long-term success.

The fabrication of a complete-arch, fixed detachable implant prosthesis is technically demanding. Porcelain contracts after firing, and this has the potential to distort the ceramometal framework unless appropriate measures are taken to control and prevent warping. The use of cross-arch stabilization bars (Fig 5) provides casting rigidity, prevents distortion, and maintains optimal fit.<sup>33</sup>

The survival of each implant was evaluated at the time of abutment connection by means of a mobility test; following placement of the prostheses, survival was assessed by means of marginal bone maintenance as seen on panoramic radiographs, and by the absence of pain or symptoms of infection. Including the pterygomaxillary implants, the cumulative implant survival rate (CSR) of all maxillary implants in this study was 92.1%; when excluding the pterygomaxillary positions, the CSR was 93%.

The cumulative survival rate (CSR) of the maxillary implants in this study (92%) is more favorable than the 72.4% CSR reported by Jemt et al<sup>34</sup> in a 5-year prospective multicenter report on maxillary overdentures supported by osseointegrated implants. In that study, 30 patients received 117 Brånemark implants in the maxilla; 4 patients converted to fixed prostheses. Jemt reported hyperplasia as a common occurrence under maxillary overdentures; however, no hyperplasia was evident under the fixed prostheses in this study. In the present review, 1 patient, who was unhappy with a maxillary overdenture supported by 4 anterior implants, converted to a fixed prosthesis with the addition of 2 pterygomaxillary implants (Fig 2).

The success rate for implants placed in the pterygomaxillary region was 88.2%, which compares favorably with the results of previous studies of implants placed in the maxillary arch.<sup>19,20,34</sup> It is important to note that most of the previous studies on implants placed in the maxilla analyzed implants that were placed primarily anterior to the antrum and only occasionally beneath it. This is noteworthy, because the general quality of bone in the anterior maxilla is usually superior to that found in the posterior maxilla. Implant loss in the maxilla<sup>26</sup> had previously been related to short (7.0-mm) implants that were placed in trabecular bone and supported distal cantilevered pontics. In addition, parafunctional habits that exert excessive occlusal forces, mainly in the molar region, had been noted as a factor for loss of osseointegration in these implants.<sup>35</sup> Longer and wider implants, which have a surface area greater than the standard  $10 \times 3.75$ -mm implant, are recommended for bone Types III and IV in the posterior maxilla to alleviate these problematic situations.

In 1992, Balshi<sup>36</sup> reported favorable 3-year results for implants placed in the pterygomaxillary region. He later reported on a study of implants that were placed in the pterygomaxillary region and supported fixed prostheses in partially edentulous patients.<sup>14</sup> Bahat<sup>37</sup> reported on 72 implants placed in the tuberosity region, which achieved a 93% survival rate over an average loading time of 1.7 years. Tulasne<sup>30</sup> addressed the use of 13 implants placed in the pterygomaxillary region in function for 12 months. In 1994, Khayat and Nader<sup>38</sup> reported on implants in the pterygoid position followed over a 4-year period. Also in 1994, Graves<sup>39</sup> described 43 implants in the pterygoid plate area. The total number of implants in these 5 studies was 244: 51 in Balshi, 72 in Bahat, 13 in Tulasne, 65 in Khayat and Nader, and 43 in Graves. The studies had widely variable follow-up times, but produced relatively consistent cumulative survival rates (CSR) above 86.0%. However, in this single-center study, the CSR of 356 implants placed in the pterygomaxillary area and in function from 6 months to 9.5 years is 88.2%.

No incidences of extraordinary complications were noted in this study or in the previously published studies of implants placed in the pterygomaxillary region. Patient acceptance of distally and palatally positioned prosthetic components and bars in this study has been excellent. A complete anatomic tooth below the pterygomaxillary implant is not as easily tolerated as a low-profile connector bar. While oral hygiene and plaque control may be more challenging in the posterior

region, there have been no reported losses of Brånemark implants as a result of plaque accumulation or tissue hyperplasia. None of the pterygomaxillary implants had associated mucosal inflammation. Highly polished prostheses can be fabricated for optimal plaque control.<sup>40</sup>

## Conclusion

Pterygomaxillary implants are beneficial in restoring the entire maxillary arch with a prosthesis that is biomechanically stable and free of cantilevered pontics. Implants placed in the pterygomaxillary area assist in stabilizing bone-anchored prostheses in completely edentulous patients. In this retrospective investigation, 356 of 1,817 implants were placed in the pterygomaxillary area of 189 edentulous maxillae, with a cumulative survival rate of 88.2% during a mean loading period of 4.68 years. The cumulative survival rate (CSR) of pterygomaxillary implants compares favorably with implants used in other areas of the maxilla, despite the compromised quality of bone and increased potential for force exerted on implants placed in the posterior maxilla. Implants placed in the pterygomaxillary region provide posterior bone support without sinus augmentation or supplemental grafting.

## Acknowledgments

The authors thank Chris Raines for computer graphics, Liz Kirk for manuscript preparation, and Robert Winkelman, CDT, MDT, and the staff of Fort Washington Dental Lab for prosthesis fabrication.

## References

1. Brånemark P-I, Hansson BO, Adell R, Breine U, Lindström J, Hallén O, Ohman A. Osseointegrated implants in the treatment of the edentulous jaw. Experience from a 10-year period. *Scand J Plast Reconstr Surg* 1977;16(suppl).
2. Adell R, Lekholm U, Rockler B, Brånemark P-I. A 15-year study of osseointegrated implants in the treatment of the edentulous jaw. *Int J Oral Surg* 1981;10:387-416.
3. Lekholm U. The Brånemark implant technique: A standardized procedure under continuous development. In: Lancy WR, Tolman DE (eds). *Tissue Integration in Oral, Orthopedic and Maxillofacial Reconstruction*. Chicago: Quintessence, 1990:194-199.
4. Albrektsson T, Dahl E, Enbom L, Engevall S, Engquist B, Eriksson A, et al. Osseointegrated oral implants: A Swedish multicenter study of 8139 consecutively inserted Nobelpharma implants. *J Periodontol* 1988;59:287-296.
5. Albrektsson T, Zarb GA, Worthington P, Eriksson A. The long-term efficacy of currently used dental implants: A review and proposed criteria of success. *Int J Oral Maxillofac Implants* 1986;1:11-26.



6. Van Steenberghe D, Quirynen M, Calberson L, Demane M. A prospective evaluation of the fate of 697 consecutive intraoral fixtures ad modum Brånemark in the rehabilitation of edentulism. *J Head Neck Pathol* 1987;6:53-58.
7. Zarb GA, Zarb FL, Schmitt A. Osseointegrated implants for partially edentulous patients. *Dent Clin North Am* 1987;31:457-472.
8. Lekholm U, Adell R, Brånemark P-I. Possible complication. In: Brånemark P-I, Zarb GA, Albrektsson T (eds). *Tissue-Integrated Prostheses: Osseointegration in Clinical Dentistry*. Chicago: Quintessence, 1985:233-240.
9. Brånemark P-I, Adell R, Albrektsson T, Lekholm U, Lindström J, Rockler B. An experimental and clinical study of osseointegrated implants penetrating the nasal cavity and maxillary sinus. *J Oral Rehabil* 1979;43:497-505.
10. Tatum H. Maxillary and sinus implant reconstruction. *Dent Clin North Am* 1986;30:207-229.
11. Harlson T, Karlsson U, Carlsson GE. Bite force and oral function in complete denture wearers. *J Oral Rehabil* 1979;6:41-48.
12. Reiger MR. Loading considerations for implants. *Oral Maxillofac Clin North Am* 1991;3:795-804.
13. Langer B, Langer L, Herrman I, Jorneus L. The wide fixture: A solution for special bone situations and a rescue for the compromised implant. *Int J Oral Maxillofac Implants* 1993;8:400-408.
14. Balshi TJ, Lee HY, Hernandez R. The use of pterygomaxillary implants in the partially edentulous patient: A preliminary report. *Int J Oral Maxillofac Implants* 1995;10:89-98.
15. Kent JN, Block MS. Simultaneous maxillary sinus floor bone grafting and placement of hydroxyapatite-coated implants. *J Oral Maxillofac Surg* 1989;47:238-242.
16. Wood RM, Moore DL. Grafting of the maxillary sinus with intraorally harvested autogenous bone prior to implant placement. *Int J Oral Maxillofac Implants* 1988;3:209-214.
17. Boyne PJ, James RA. Grafting of the maxillary sinus floor with autogenous marrow and bone. *J Oral Surg* 1980;38:613-616.
18. Hirsch JM, Ericsson I. Maxillary sinus augmentation using mandibular bone grafts and simultaneous installation of implants. *Clin Oral Implants Res* 1991;2:91-96.
19. Jaffin RA, Berman CL. The excessive loss of Brånemark fixtures in type IV bone: A 5-year analysis. *J Periodontol* 1991;62:2-4.
20. Schnitman P, DaSilva J, Wöhrle P, Wang H, Koch G. Influence of site on implant survival: Seven-year results [abstract 1664]. *J Dent Res* 1993;72(3)(special issue):311.
21. Brunski JB. Biomechanics of oral implants: Future research directions. *J Dent Educ* 1988;52:775-787.
22. Martel MH. About single units, abutments, and interlocks, implants and experts. Presented at the American Academy of Fixed Prosthodontics, Chicago, 19-20 Feb 1993.
23. Gibbs C, Mahan P, Mauderli A. Limits of human bite strength. *J Prosthet Dent* 1986;56:226-237.
24. Hagberg C. Assessment of bite force: A review. *J Cranio-mandib Disord Facial Oral Pain* 1987;1:162-169.
25. Brunski JB. Forces on dental implants and interfacial stress transfer. In: Laney WR, Tolman DE (eds). *Tissue Integration in Oral, Orthopedic and Maxillofacial Reconstruction*. Chicago: Quintessence, 1990:108-124.
26. Balshi TJ. Preventing and resolving complications with osseointegrated implants. *Dent Clin North Am* 1989;33:821-868.
27. Rangert B, Krogh P, Langer B, Van Roekel N. Bending overload and implant fracture: A retrospective clinical analysis. *Int J Oral Maxillofac Implants* 1995;10:326-334.
28. Rangert B, Jemt T, Jorneus L. Forces and moments on Brånemark implants. *Int J Oral Maxillofac Implants* 1989;4:241-247.
29. Watson CJ, Ogden AR, Tinsley D, Russell JL, Davison EM. A 3- to 6-year study of overdentures supported by hydroxyapatite-coated endosseous dental implants. *Int J Prosthodont* 1998;11:610-619.
30. Tulasne JF. Implant treatment of missing posterior dentition. In: Albrektsson T, Zarb GA (eds). *The Brånemark Osseointegrated Implant*. Chicago: Quintessence, 1989.
31. Kopp CD. Brånemark osseointegration. Prognosis and treatment rationale. *Dent Clin North Am* 1989;33:701-731.
32. Lekholm U, Zarb GA. Patient selection and preparation. In: Brånemark P-I, Zarb GA, Albrektsson T (eds). *Tissue-Integrated Prostheses: Osseointegration in Clinical Dentistry*. Chicago: Quintessence, 1995:199-209.
33. Winkelman R, Orth K. *Dental Implants: Fundamental and Advanced Laboratory Technology*. London: Wolfe, 1994.
34. Jemt T, Chai J, Harnett J, Heath MR, Hutton JE, Johns RB, et al. A 5-year prospective multicenter follow-up report on overdentures supported by osseointegrated implants. *Int J Oral Maxillofac Implants* 1996;3:291-298.
35. Balshi TJ. Overload management of osseointegrated fixtures to achieve optimum bone remodeling through multi-stage prosthodontic loading. In: Laney WR, Tolman DE (eds). *Tissue Integration in Oral, Orthopedic and Maxillofacial Reconstruction*. Chicago: Quintessence, 1990:364-371.
36. Balshi TJ. Single tuberosity osseointegrated implant support for a tissue integrated prosthesis. *Int J Periodontics Restorative Dent* 1992;12:345-357.
37. Bahat O. Osseointegrated implants in the maxillary tuberosity: Report of 45 consecutive patients. *Int J Oral Maxillofac Implants* 1992;7:459-467.
38. Khayat P, Nader N. The use of osseointegrated implants in the maxillary tuberosity. *Pract Periodontics Aesthet Dent* 1994;6:53-61.
39. Graves S. The pterygoid plate implant: A solution for restoring the posterior maxilla. *Int J Periodontics Restorative Dent* 1994;14:513-523.
40. Balshi TJ. Hygiene maintenance procedures for patients treated with the tissue integrated prosthesis (osseointegration). *Quintessence Int* 1986;17:95-102.